FRANK ARGUELLO, MD

Director, Atavistic Chemotherapy Trial

www.AtavisticChemotherapy.com

Frm. Assistant Professor of Oncology,
and Pediatrics, Hematology and Oncology, University
of Rochester School of Medicine and Dentistry.
Rochester, New York USA.
Frm. Senior Scientist,
Division of Cancer Treatment & Diagnosis, National
Cancer Institute, National Institutes of Health.
Frederick, Maryland USA.

Tel (301) 760-7777;
Fax (301) 690-9000
arguellof@atavisticchemotherapy.com

TREATMENT FOR EARLY BREAST CANCER

1st Century
Simple Mastectomy -/+
Axillary Lymph Nodes

16th Century
Bilateral Mastectomy +/Removal
of Axillary Lymph Nodes

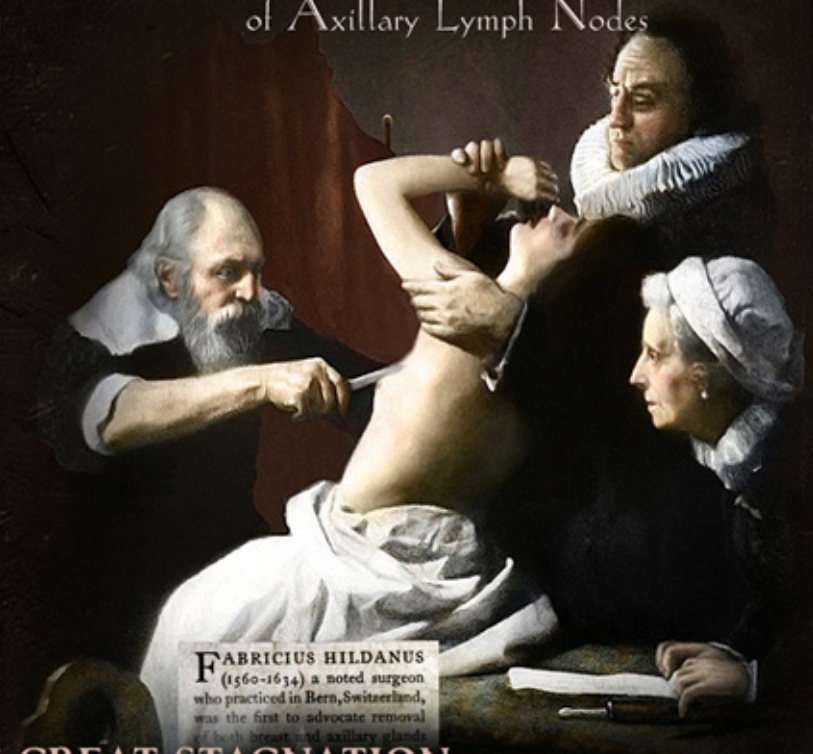

FABRICIUS HILDANUS (1560-1634) a noted surgeon who practiced in Bern, Switzerland, was the first to advocate removal of both breast and axillary glands

THE GREAT STAGNATION:
Why Haven't We Progressed for Centuries?

If we need to do this to patients with breast cancer who have localized tumors to the breast, and with sizes as small as a pea or grape, what can we realistically offer to those breast cancer patients who develop multiple metastatic tumors in the skin, lungs, bones, liver or brain, with sizes as big as softball balls?

Is **Atavistic Metamorphosis** the correct biological explanation of malignant transformation and the biological bases to treat cancer correctly and without barbaric toxicity capable of leaving a person infertile or with an increased risk for a second cancer?

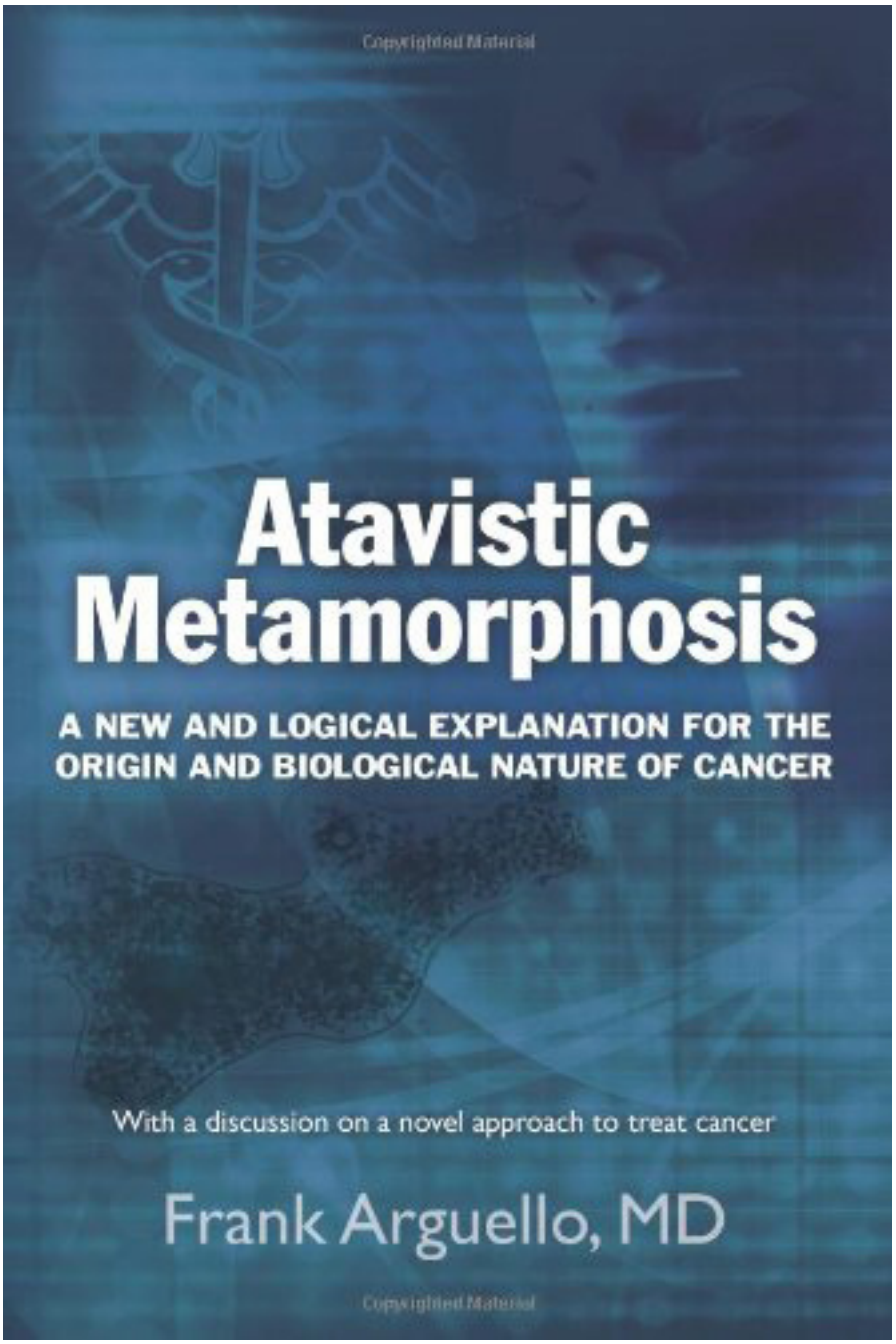

BREAST CANCER PATIENTS TREATED WITH TARGETED ATAVISTIC CHEMOTHERAPY

THESE ARE PATIENTS WHO HAD EXPERIENCED CANCER RECURRENCE YEARS AFTER SURGERY, TRADITIONAL CHEMOTHERAPY AND/OR RADIATION, OR WHO WHERE REGARDED AS HOPELESS CASES

Locally Advanced Breast Cancer Consumed Breast and Invades Muscle and Pleura.

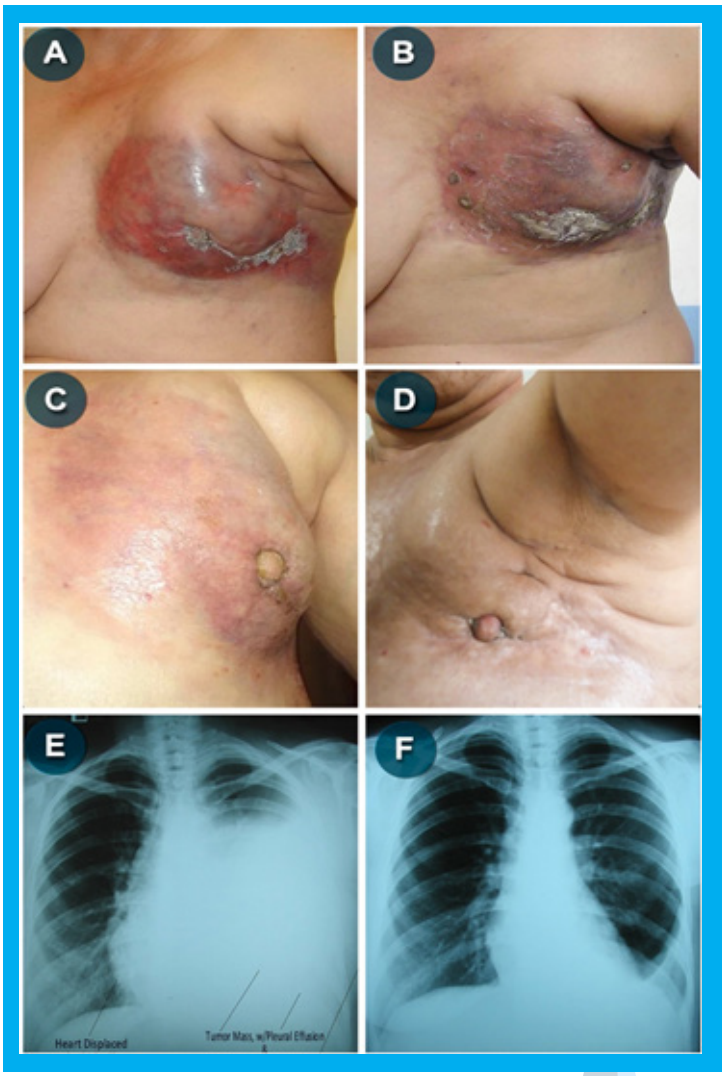

Patient was treated with traditional chemotherapy. After the fifth cycle, she chose to discontinue this treatment because of intolerance. After 12 months without formal treatment, the patient presented to our clinic with intense pain and shortness of breath. (A) At the time of enrollment, her cancer had "digested" and replaced the entire left breast and was invading the anterior and lateral chest wall. (B) After 1 month of atavistic chemotherapy, tumor vascularity had markedly decreased, and (C) a complete clinical response was evident within 6 months of the initiation of therapy. (D) At 20 months, marked fibrosis and retraction were evident. (E) Radiological studies initially revealed tumor infiltration into all soft tissue structures up to the pleural cavity, with a massive pleural effusion; evidence of resolution was documented after 6 months of treatment. (F) A small loculated effusion that tested negative for malignant cells persisted in the left costodiaphragmatic angle. The patient also had a 3.2 cm liver metastasis that was no longer visible after 3 months of atavistic chemotherapy.

Malignant Ulcer, Recurrent and Metastatic Adenocarcinoma of the Right Breast

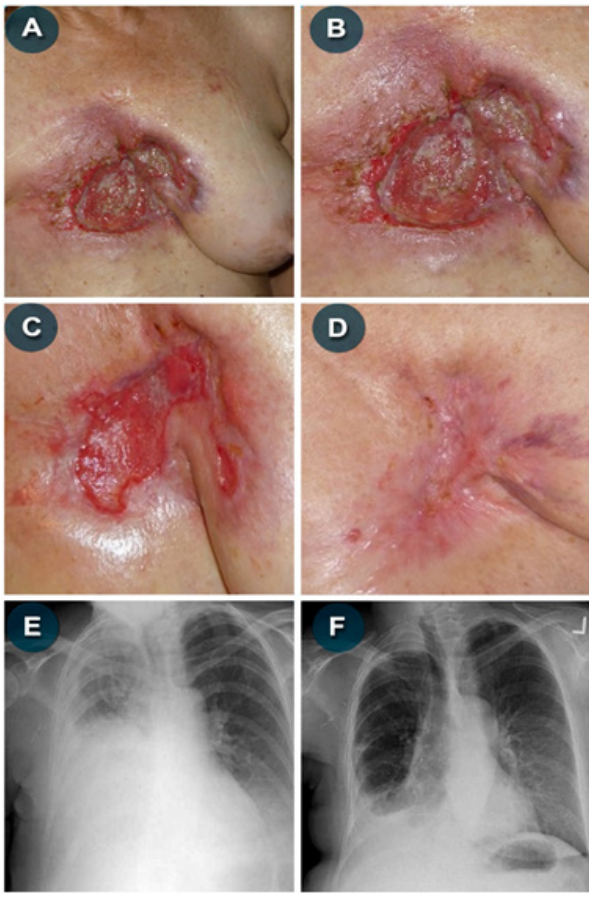

Patient was treated with traditional chemotherapy followed by a modified radical mastectomy and 25 sessions of radiation. She continued taking letrozole for 2 years. Approximately 24 months after the operation, recurrence in the surgical scar was documented. (A and B) By the time she entered our trial (at age 62), the cancer had "consumed" part of the soft tissue of the anterior chest wall, involving an area about 13 cm × 10 cm, and had invaded the left breast. (C) Healing was evident 9 weeks after the initiation of atavistic chemotherapy and (D) was complete after approximately 6 months of treatment. At the time of recurrence, a CT scan and MRI showed an irregular 5 cm × 4 cm metastatic tumor in the right parietal pleura next to the cardiophrenic angle, which also affected the pericardium and left pleura. (E) Prior to trial entry, bilateral pleural effusions had developed and a pleurodesis performed in the right lung prior to atavistic chemotherapy. (F) A chest X-ray taken 6 months after the initiation of atavistic chemotherapy shows both lungs inflated; post-pleurodesis changes are also evident at the base of the right chest.

Triple-Negative Recurrent Breast Cancer.

After a lumpectomy, the patient underwent conventional chemotherapy and radiation, but 12 months later, she had local recurrence at the surgical scar, and a modified radical mastectomy of the right breast was performed.



Two months later, a second local recurrence at and around the surgical scar was detected, and palliative conventional chemotherapy was initiated. When the tumor continued to progress despite treatment, conventional chemotherapy was discontinued after four cycles. (A) By the time the patient enrolled in our trial (at age 65), several raised islands of highly vascularized tumors had infiltrated the skin at and around the surgical scar and the left breast.

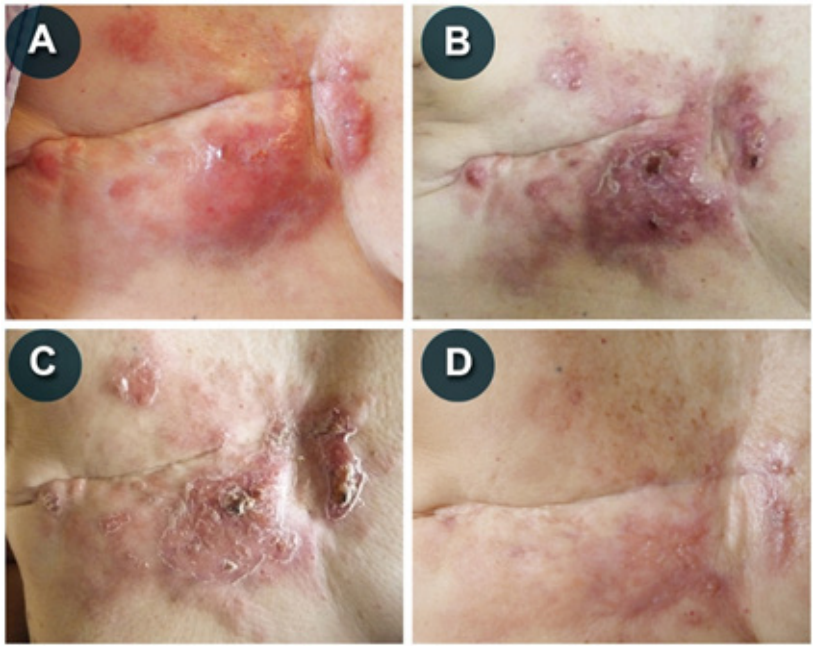

(B) Three days after the initiation of atavistic chemotherapy, the tumors appeared pale and dry with small vesicles. (C) Ten days later, the tumors had flattened out, and superficial tissue had begun to peel off. (D) Three months later, the surrounding skin appeared to be near normal, and scar tissue had developed.

Inflammatory Breast Cancer of the Right Breast.

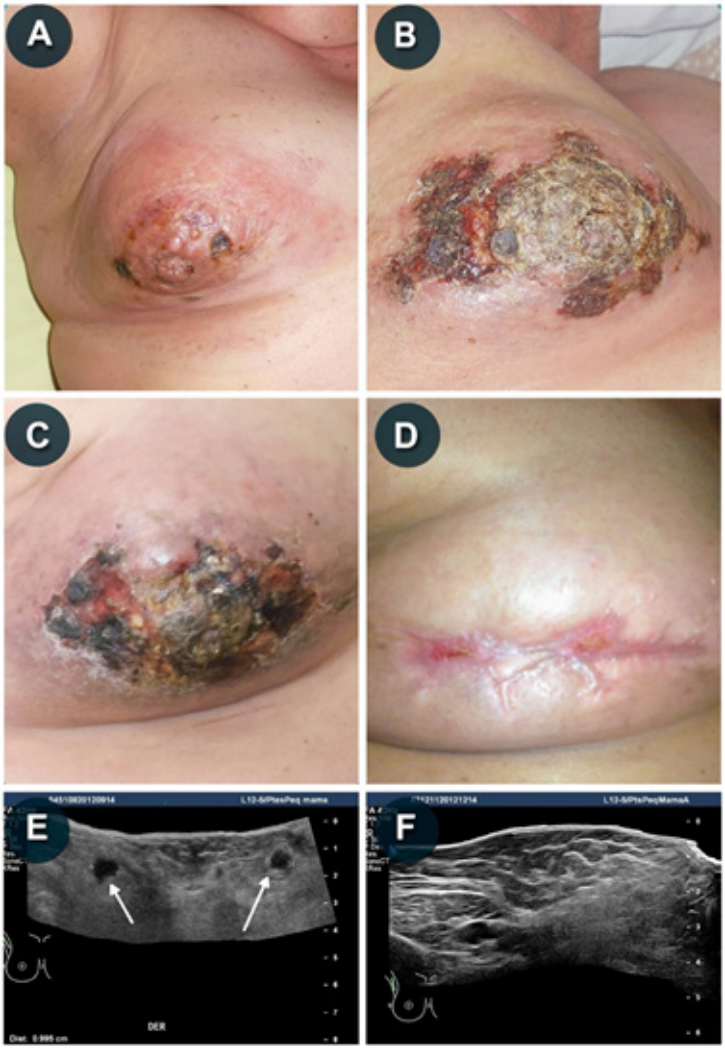

On the basis of a poor prognosis explained to the patient, she did not wish to undergo conventional chemotherapy and presented (at age 68) with what appeared to be an inflammatory breast cancer that had invaded the skin and areola of the right breast. (B) After 4 weeks and (C) 8 weeks of atavistic chemotherapy, the diseased area became necrotic, causing inflammation and painful retraction of the skin that required debridement. (D) Healing was complete 9 months after the initiation of treatment. (E) During the initial examination, lymph nodes (arrows) had been visible on ultrasonography. (F) Six months later, the lymph nodes were no longer visible

Inoperable, Locally Advanced Invasive Ductal Adenocarcinoma of the Left Breast.

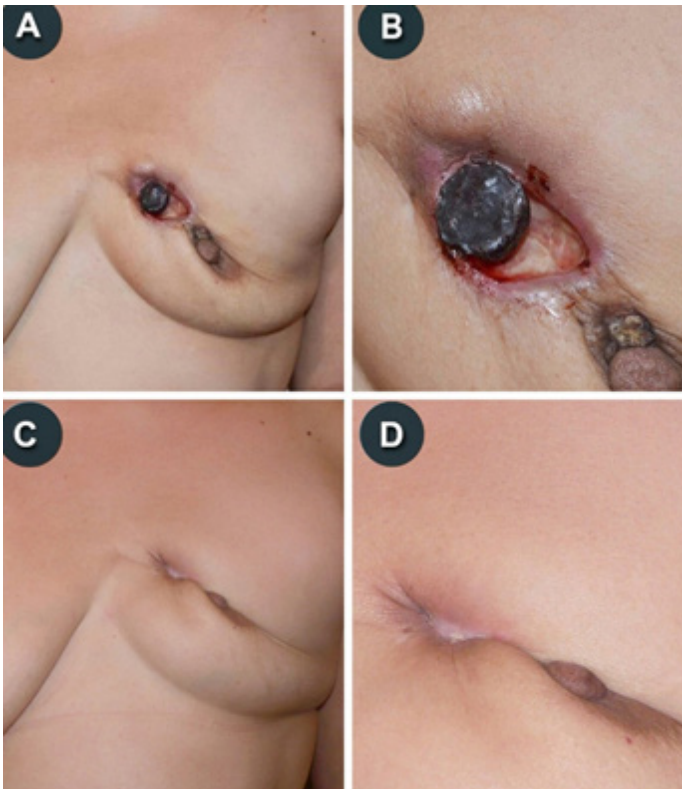

This patient had forgone formal medical treatment for 4 years after the diagnosis of breast cancer. Although pain and bleeding forced her to accept palliative conventional chemotherapy, she discontinued it after two cycles because of intolerance. (A) By the time she enrolled in our trial (at age 46), the cancer had "digested" the entire left breast and was invading the anterior and lateral chest wall. (B) A malignant ulcer had developed in the affected breast, with bleeding and a putrid discharge, and clot retraction had resulted in an eye-like appearance. (C and D) A complete clinical response was evident within 6 months of treatment, which led to marked fibrosis and retraction.

Large Inoperable Breast Cancer in a 75-year Old Patient

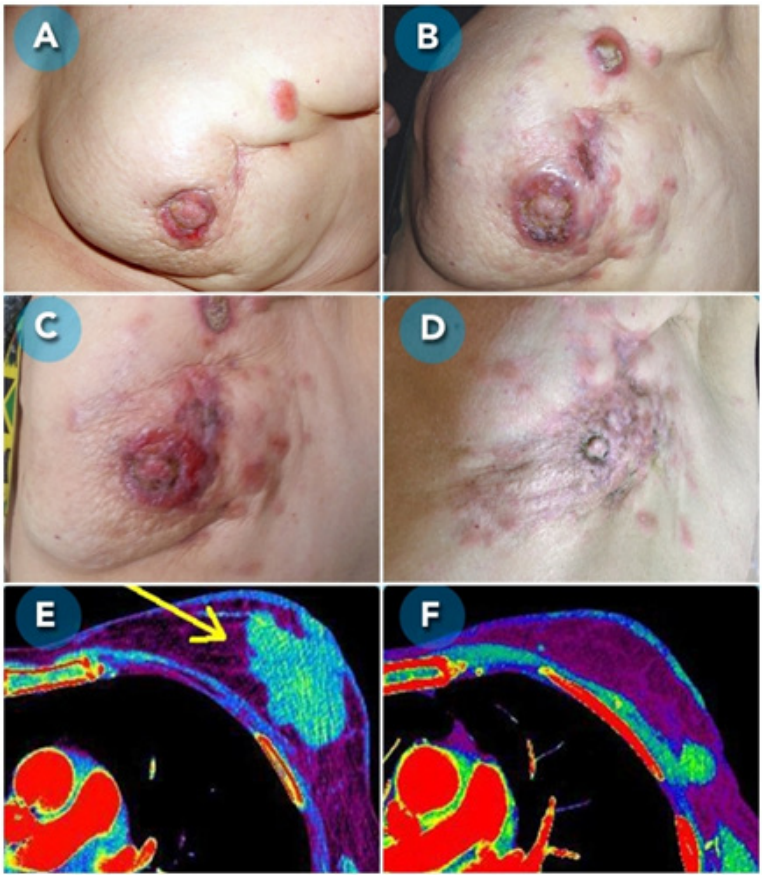

Locally advanced cancer of the left breast, four years after diagnosis. However, patient rejected mastectomy or traditional chemotherapy. (A) When seen for the first time in our clinic the left breast had a bulky appearance and deformed. Several lymph nodes were palpable in the left axillary region. (B) Appearance of the breast one month after initiation of atavistic chemotherapy. (C) After three months of atavistic chemotherapy, the breast has lost 80% of its initial volume. (D) Brest is now totally flat, showing several skin colonies of cancer being removed by an inflammatory process.

Recurrent Breast Cancer Growing in the Skin around area of Past Mastectomy, Front of Chest, Neck and Back.

Two years after radical mastectomy, traditional chemotherapy and radiation, patient suffered a recurrence of her breast cancer in the skin surrounding the surgical scar. Despite traditional chemotherapy, the cancer progressed and extended progressively throughout the skin of the chest, neck and back. Pictures below show the front and back of the patient. (A) Prior to atavistic chemotherapy. (B) Only 10 days after initiation of atavistic chemotherapy; and (C) About 30 days after initiation of treatment. Patient initiated treatment on September 1, 2017, if interested in her evolution please request new images.

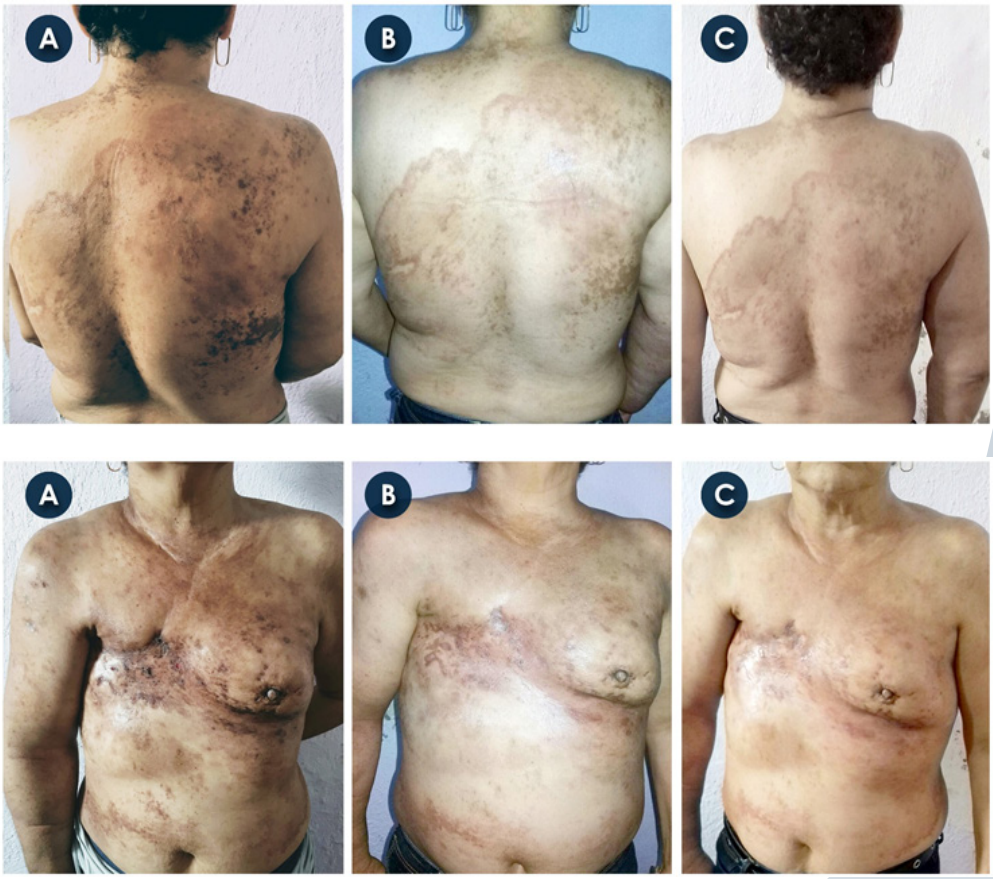

Below is our most recent breast cancer case, being administered by our partner in Bangalore, India, Dr. Jagadish Donki (http://integrativecancertherapycenter.com).

Patient rejected radical mastectomy at the time of diagnosis of a breast cancer localized in the upper left quadrant of the left breast. She continued with naturopathic treatments until November 2017 when presented in Dr. Donki's clinic with a large highly vascularized tumor localized in the upper left quadrant of the left breast, and with a metastatic tumor in the scalp with the same highly vascularized characteristics.

Below, (A) Aspect of the primary tumor in the breast prior to initiation of atavistic chemotherapy. (B) Same tumor as A, but 9 days after initiation of atavistic chemotherapy. (C)) Aspect of metastatic tumor in the scalp of the patient, prior to initiation of atavistic chemotherapy. (D) Same tumor as C, but 9 days after initiation of atavistic chemotherapy. **Patient initiated treatment on November 10, 2017, request updated images if interested in her evolution.**